



PRESENTING CLINICAL SIGNS

DATE History: Recheck DMVD. Receiving pimobendan 1.25 mg am, 0.625 mg pm. Asymptomatic.

ECHOCARDIOGRAPHIC FINDINGS

2D, M-mode, and Doppler study. This exam is compared to the one performed 11/10/21.

PERFORMED BY: There is mild left atrial dilation. The mitral valve leaflets are mildly thickened and exhibit mild systolic prolapse. There is Doppler evidence of mitral regurgitation present. There is mild left ventricular dilation. Left ventricular systolic function is hyperdynamic. The aorta and aortic valve are normal. Right atrial and right ventricular dimensions are normal. The tricuspid valve is normal. The pulmonary artery and pulmonic valve are normal. No pericardial effusion or cardiac masses are seen.

Dr. Meredith Swart

INTERPRETED BY

Keith Blass, DVM,
MS, DACVIM
(Cardiology)

LA - 25.8 mm (prev. 25.6 mm)
LVIDd - 24.8 mm (prev. 24.7 mm)
LVIDs - 13.3 mm (prev. 11.6 mm)
FS - 46% (prev. 53%)
LVOT - 1.36 m/s (prev. 1.49 m/s)
RVOT - 1.17 m/s (prev. 1.11 m/s)

PATIENT

Sissy Bracken

ASSESSMENT/RECOMMENDATIONS

Degenerative mitral valve disease

SPECIES

Canine

This examination demonstrates no progression of Sissy's mitral valve disease over the past 10 months. As such, Sissy's mitral valve disease still appears to be well-compensated, and her current risk for the development of clinical signs secondary to her disease still appears to be relatively low.

BREED

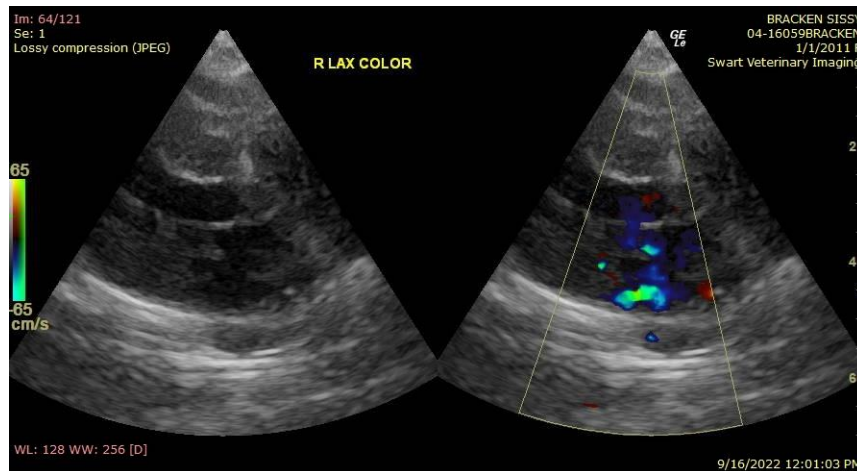
No change in therapy is recommended at this time.

Chihuahua

A recheck echocardiogram is recommended in 9 months, sooner if clinical signs compatible with cardiac dysfunction develop. Thoracic radiographs are recommended if Sissy experiences respiratory clinical signs.

SEX

FS



AGE

11 y

WEIGHT

7.1 lb

HOSPITAL NAME

Swart Veterinary
Imaging

REFERRING VET

Dr. Swart

The information and recommendations provided are based on the images presented by the referring veterinarian. No evaluation can be communicated regarding pathology that was not



visible in the image/video clips provided.

DATE

9/16/22

Thank you for this referral. If the clinical or image interpretation does not parallel your findings or if I can be of any further assistance please contact me.

PERFORMED BY:

Keith Blass, DVM, MS, DACVIM (Cardiology)
KeithBlass@gmail.com
631-804-5754

Dr. Meredith Swart

INTERPRETED BY

Keith Blass, DVM,
MS, DACVIM
(Cardiology)

PATIENT

Sissy Bracken

SPECIES

Canine

BREED

Chihuahua

SEX

FS

AGE

11 y

WEIGHT

7.1 lb

HOSPITAL NAME

Swart Veterinary
Imaging

REFERRING VET

Dr. Swart